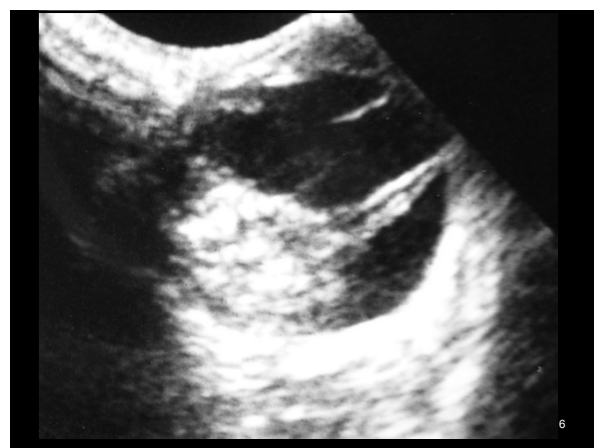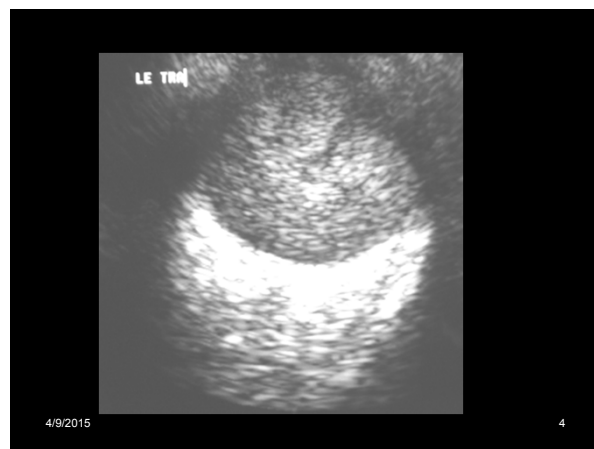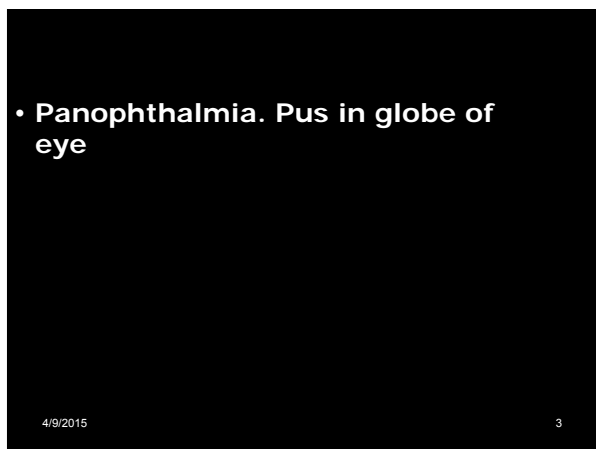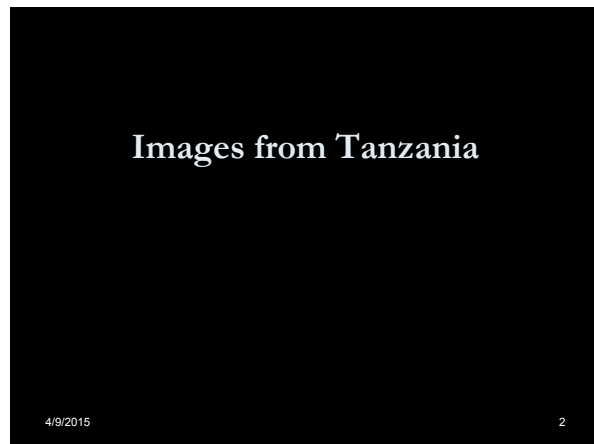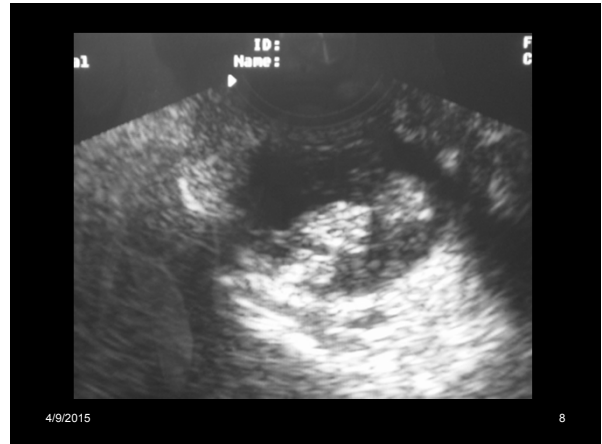


- Squamous cell carcinoma

4/9/2015

7



4/9/2015

8

- Tumor of the paranasal sinus entering orbit

4/9/2015

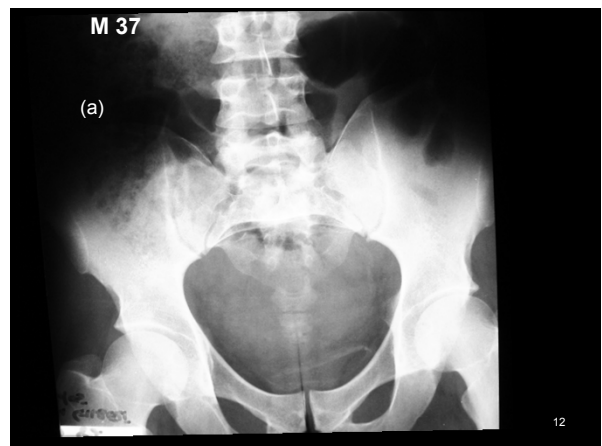
9



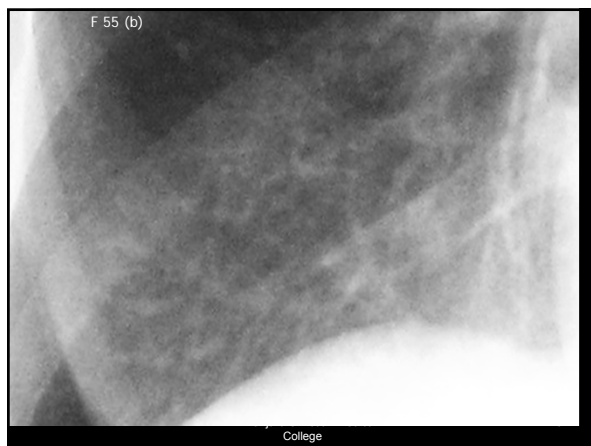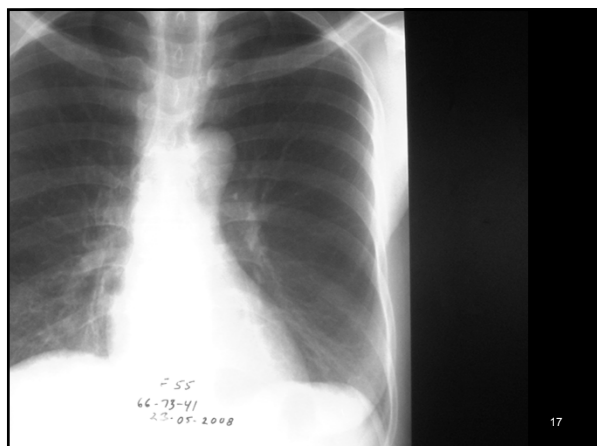
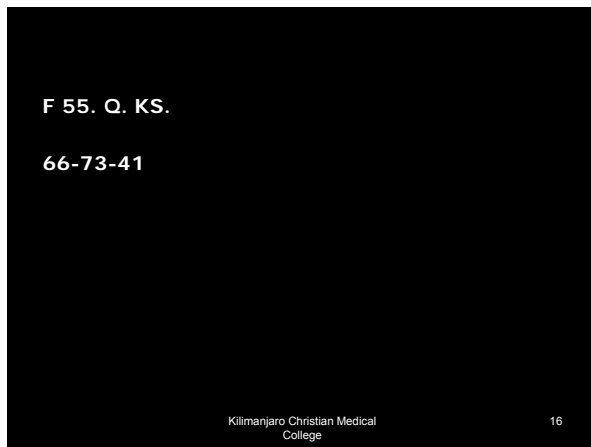
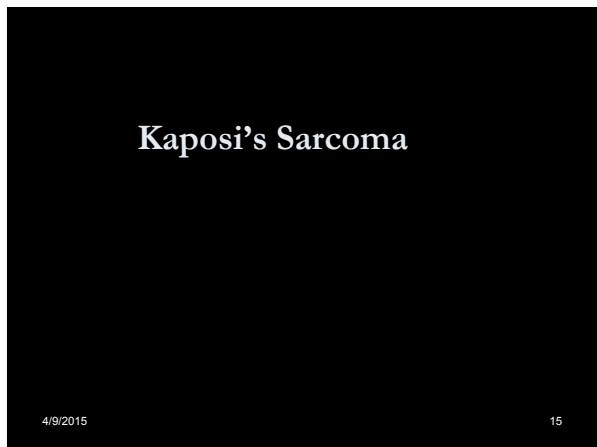
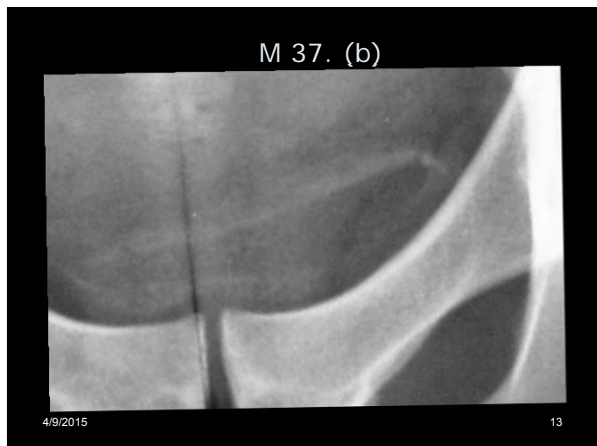- Schistosoma hematobium. M 37

4/9/2015

11



12

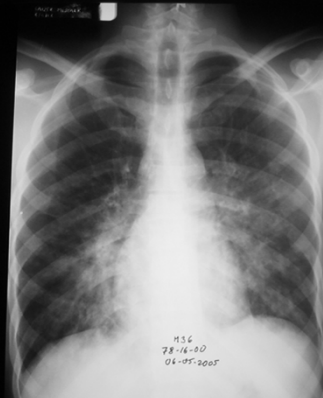


M 43. KS. Q.  
Looks like perihilar edema, but consists of  
multiple confluent nodules.  
(a-b)  
76-26-61

Kilimanjaro Christian Medical  
College

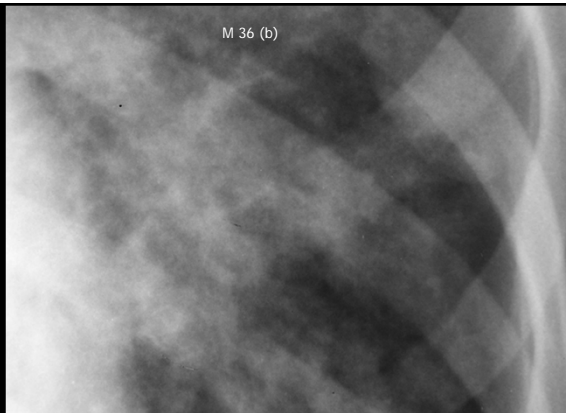
19

M 36. (a-b).  
78 16-00



20

M 36 (b)



Kilimanjaro Christian Medical  
College

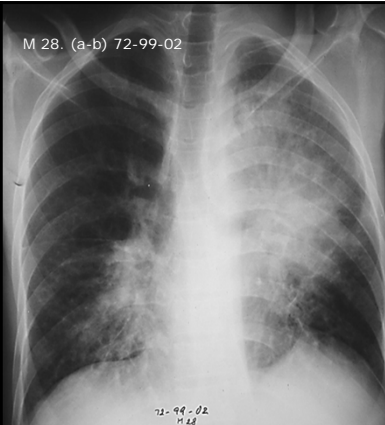
21

• M 28. Bilateral alveolar infiltrates. General  
adenopathy

Kilimanjaro Christian  
Medical College

22

M 28. (a-b) 72-99-02



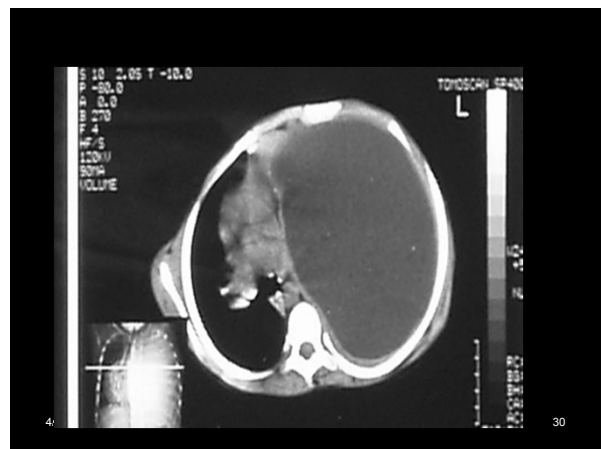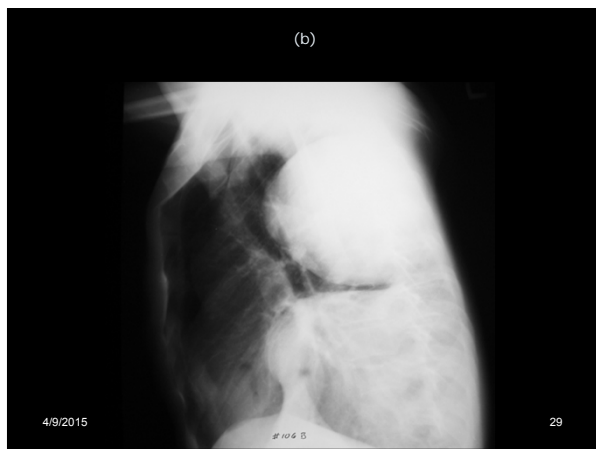
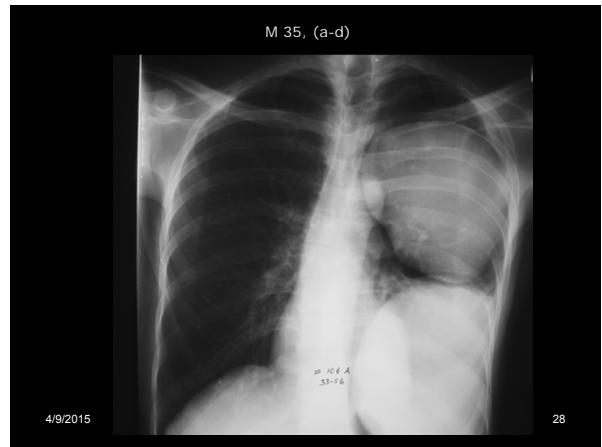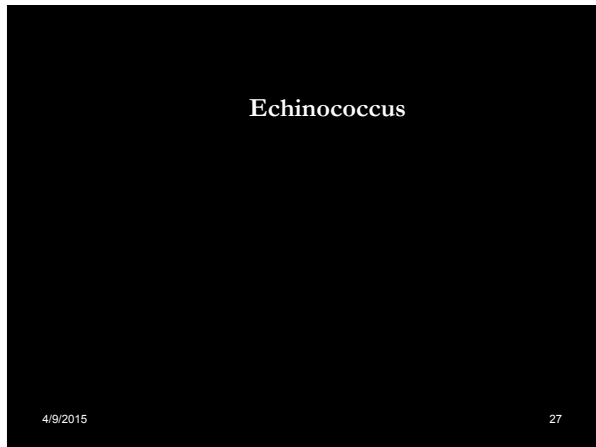
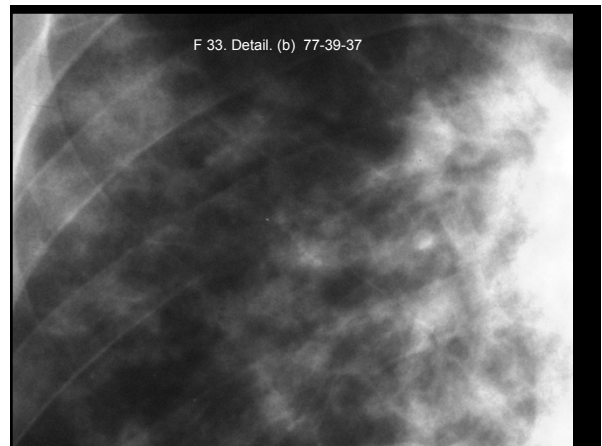
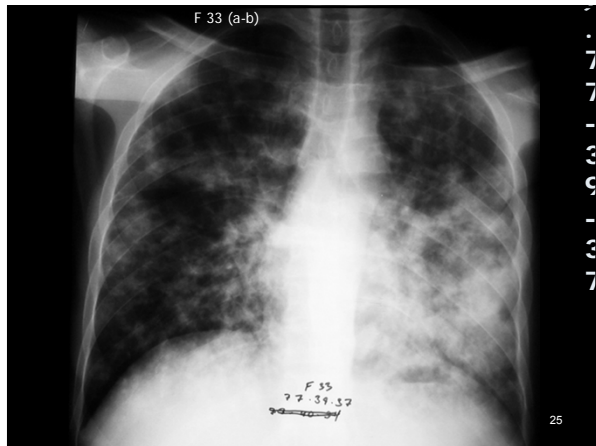
72-99-02  
1999  
Medical College

23

M 43. KS. Q.  
(a-b)  
76-26-61

Kilimanjaro Christian Medical  
College

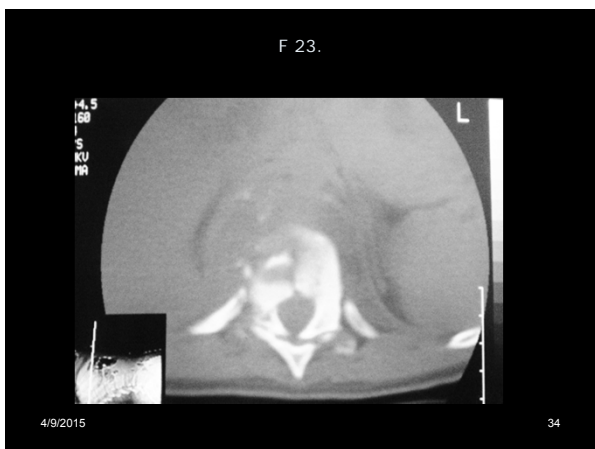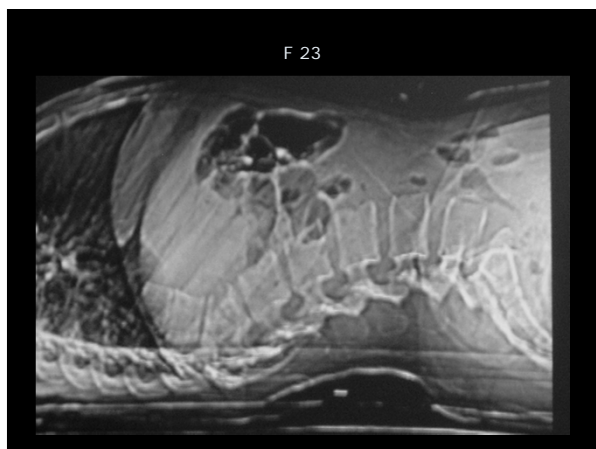
24





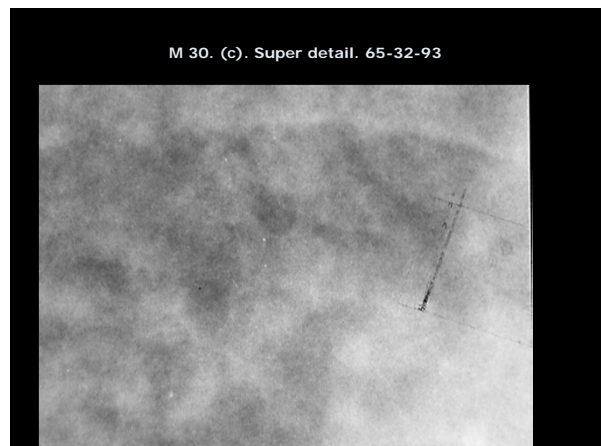
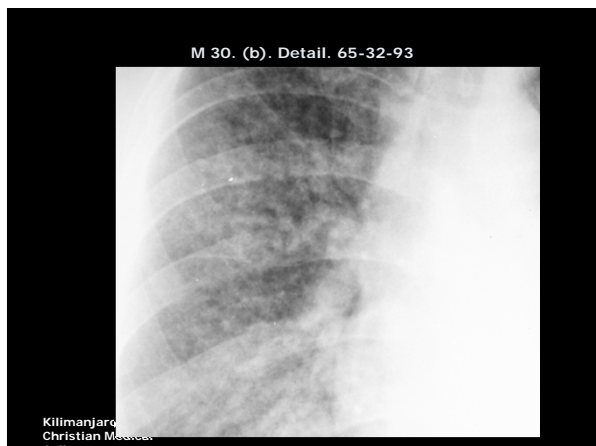
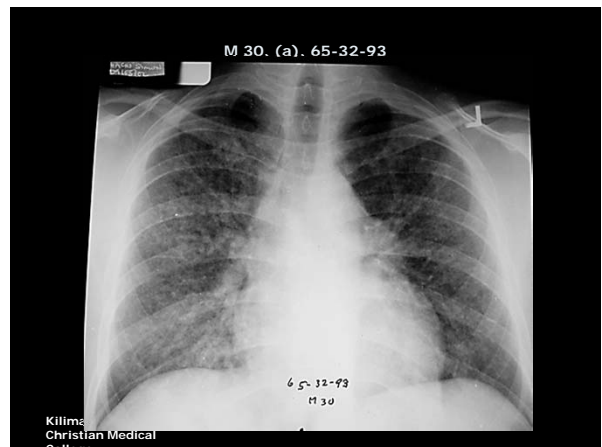
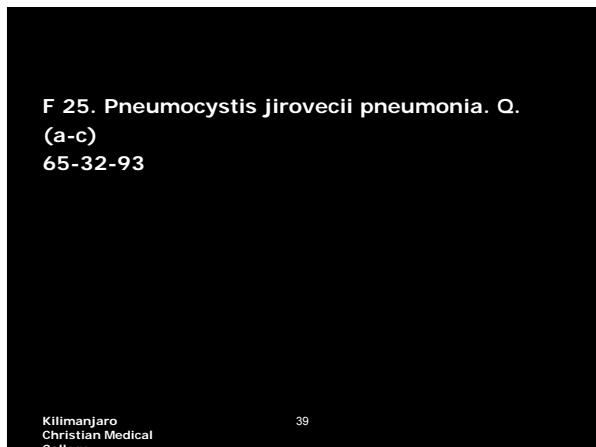
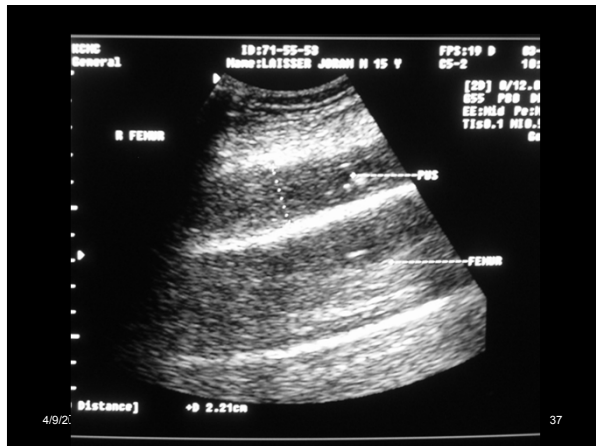- Tuberculosis of the spine

4/9/2015 32



- Early osteomyelitis

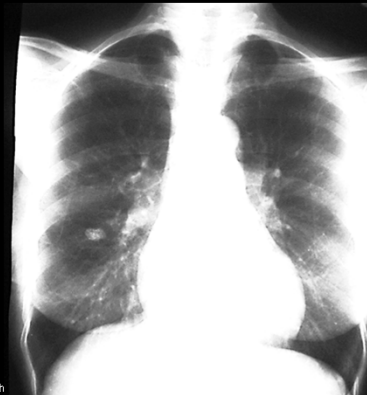4/9/2015 36



- F 64. Calcified pulmonary nodule.
- (a-b).
- 33-67-10

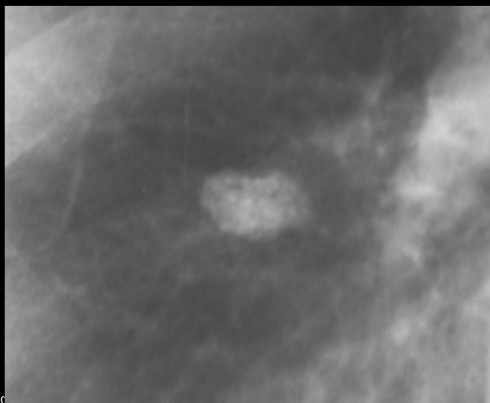
Kilimanjaro Christian Medical College 43

F 64  
(a-b)  
33-67-10.



Kilimanjaro Christian Medical College

F 64  
(b). Detail  
33-67-10

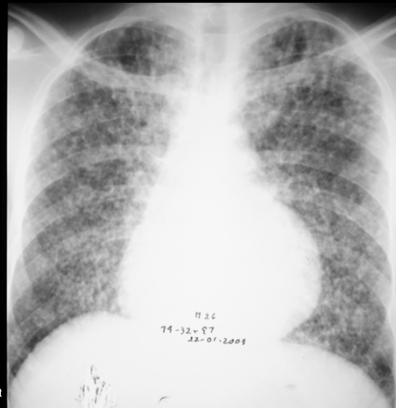

Kilimanjaro Christian Medical College

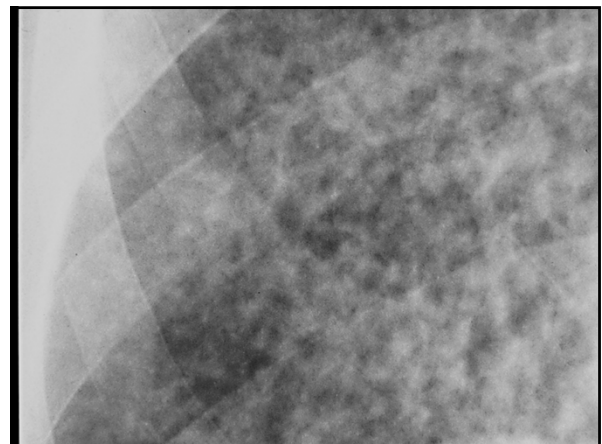
M 26. Extensive miliary lesions in both lungs.  
Blood culture: mycobacterium avium  
(a-b)  
79-32-47

Kilimanjaro Christian Medical College 46

M 26. (a)  
79-32-47



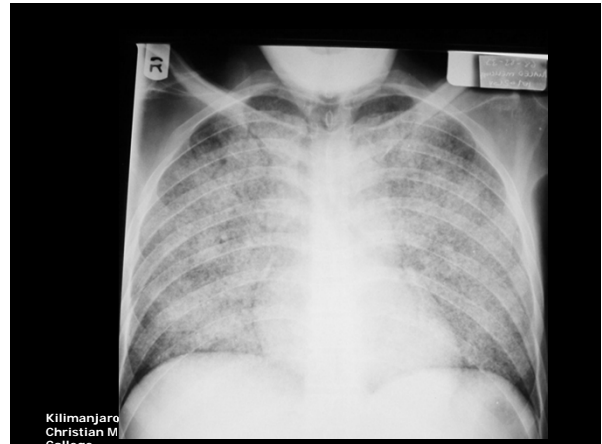
Kilimanjaro Christian Medical College



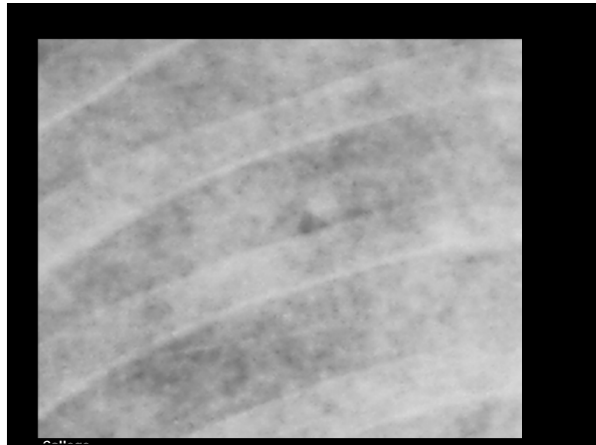


- M 45. Miliary tuberculosis. Blood culture positive
- (a-c)
- 68-83-33

Kilimanjaro Christian Medical College 49



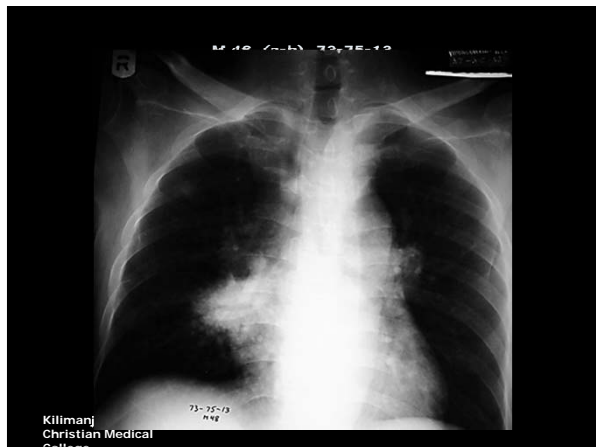
Kilimanjaro Christian Medical College




Kilimanjaro Christian Medical College

- M 48. Bronchogenic carcinoma
- One-month history of dry cough, shortness of breath, fever and loss of weight
- (a-b)
- 73-75-13

Kilimanjaro Christian Medical College 52



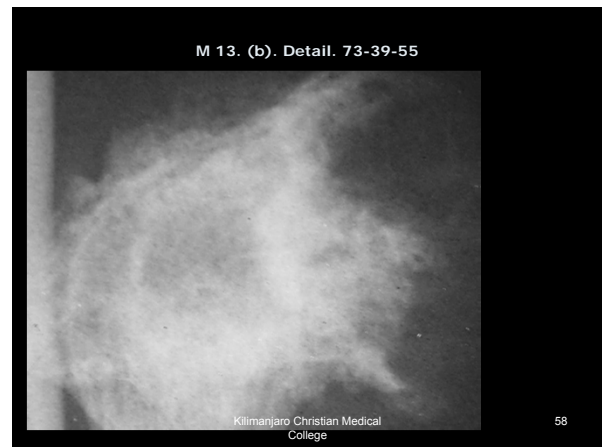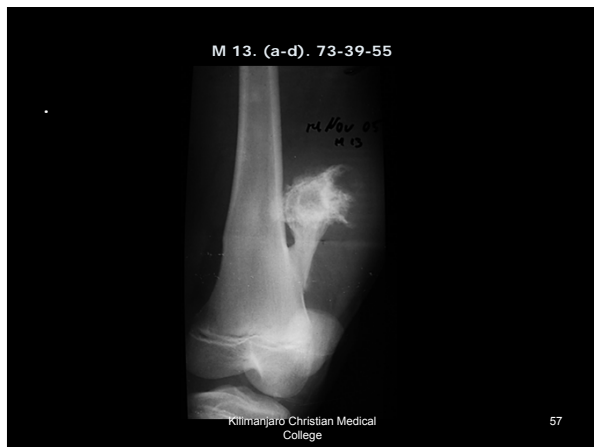Kilimanjaro Christian Medical College



Kilimanjaro Christian Medical College



- M 13. Osteochondroma with sarcomatous degeneration.
- Follow-up of 4 months.
- (a-d)
- 73-39-55



- F 13. Osteochondroma.
- (a-b)
- Swelling of right arm for 10 years.
- Suspect of malignant degeneration.



